

IMAGES IN MEDICINE

Severe functional mitral stenosis due to a left atrial myxoma

Mirsad Kacila¹, Ada Dozic², Kenan Rujanac¹

¹ Heart Center, Sarajevo, Bosnia and Herzegovina

² Department of Cardiology, General Hospital "Prim.dr. Abdulah Nakas", Sarajevo, Bosnia and Herzegovina

Corresponding Author: Ada Dozic, MD. Department of Cardiology, General Hospital "Prim.dr. Abdulah Nakas", Sarajevo, Bosnia and Herzegovina; E-mail: ada.dozic@gmail.com; Phone: +387 33 285-100; ORCID ID: 0000-0002-2664-810X

Pages: - / Published online: 30 January 2025

Cite this article: Kacila M, Dozic A, Rujanac K. Severe functional mitral stenosis due to a left atrial myxoma . Sar MedJ. 2025; 2(1): Online ahead of print. doi 10.70119/0024-25

Original submission: 24 December 2024; Revised submission: 11 January 2025; Accepted: 21 January 2025

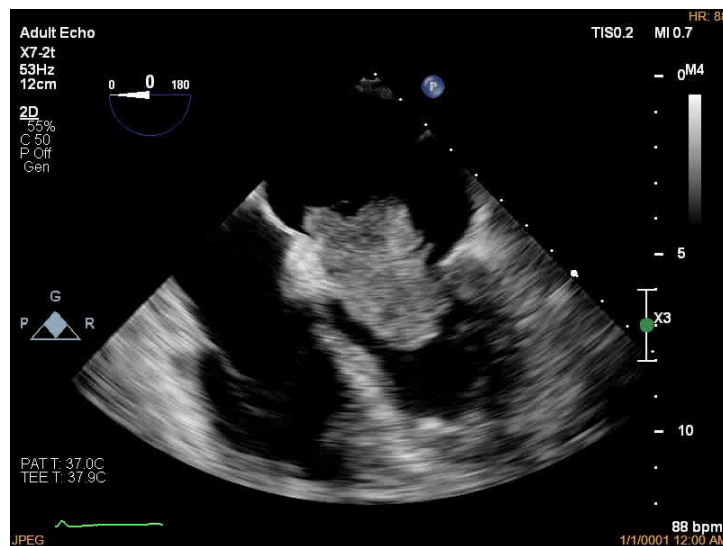


Figure 1. Obstruction of the mitral valve due to the presence of a tumor mass

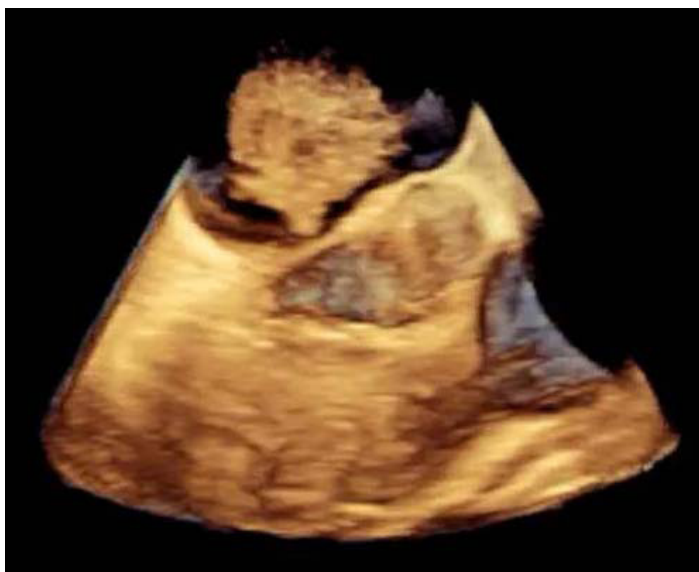

Figure 2. 3D transesophageal presentation of the tumor mass with a clear stalk which arises from the interatrial septum

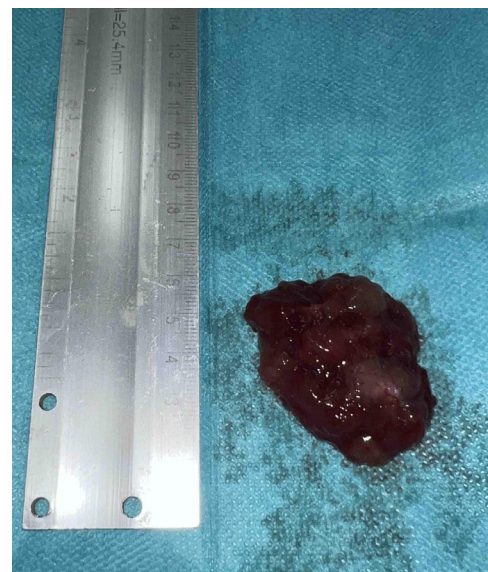


Figure 3. Surgical excision of the mass

The 71-year-old female patient was admitted for examination due to exertional intolerance. Patient's medical history included arterial hypertension and hypothyroidism. During the physical examination low-pitched sound during mid-diastole was noted, otherwise there were no remarkable findings. Laboratory findings included elevated C-reactive protein and erythrocyte sedimentation rate. There were no specific findings on ECG and chest X-ray. Two-dimensional transthoracic echocardiography (TTE) revealed a left atrial pedunculated mass, which arises from interatrial septum close to the mitral annulus, and prolapses into the mitral orifice in the diastolic phase mimicking severe mitral valve stenosis (MeanG 13 mmHg). 3D transoesophageal echocardiography (TOE) confirmed TTE findings with better assessment of tumor size (4.6 x 2.6 x 2.0 cm) and the site of tumor attachment, providing information that is even more accurate in the planning of surgical treatment. Surgical excision was performed after preoperative preparation in the ICU. Intraoperative finding included gelatinous, pedunculated left atrial mass arising from the interatrial septum (size 4,5 x

3,5 x 2.0 cm). Pathological and immunohistochemistry analysis described gelatinous structure consisting of myxoma cells embedded in a stroma, positive for calretinin, and negative for S100 protein and actin. A diagnosis of cardiac myxoma was confirmed. Myxomas are the most common type of primary cardiac tumor, with over 75% originating in the left atrium, typically at the mitral annulus or the fossa ovalis border of the interatrial septum (1-3). Patient was discharged after successful recovery (functionally without signs of mitral valve stenosis).

Consent: The author have obtained written consent from the patient to submit and publish this case report, including images and accompanying text, in accordance with COPE guidelines.

Authors' Contribution: Mirsad Kacila, Keenan Rujanac and Ada Dozic were responsible for the conceptualization, methodology, formal analysis, visualization, writing of the original draft, and the review and editing of the paper.

Conflict of interest: None declared.

Funding: None declared.

REFERENCES:

1. Zuwasti U, Quarrie R, Allen E, Haas C. Severe functional mitral stenosis due to a left atrial myxoma masquerading as asthma. *BMJ Case Rep.* 2020;13(12):e236876. doi: 10.1136/bcr-2020-236876.
2. Nguyen T, Vaidya Y. Atrial Myxoma. 2023 Jul 3. In: StatPearls [Internet]. Treasure Island (FL): StatPearls Publishing; 2025 Jan-.
3. Al-Zamkan BK, Hashem AM, Alaaeldin SA, Abdel Aziz M. An exceptionally giant left atrial myxoma: a case report and literature review. *Eur Heart J Case Rep.* 2020;4(6):1-7. doi: 10.1093/ehjcr/ytad401.